

The Canine Adrenal Glands – How to find them

JM Hanson 2012

The adrenal glands

How to localize the adrenal glands

The adrenal glands are paired glands situated retriperitoneal, craniomedial to the corresponding kidney, and lateral to the vertebrae.

-The right adrenal gland is located near the hilus of the right kidney. At the level of the 13th thoracic vertebra. The right adrenal gland is bordered by the following structures:

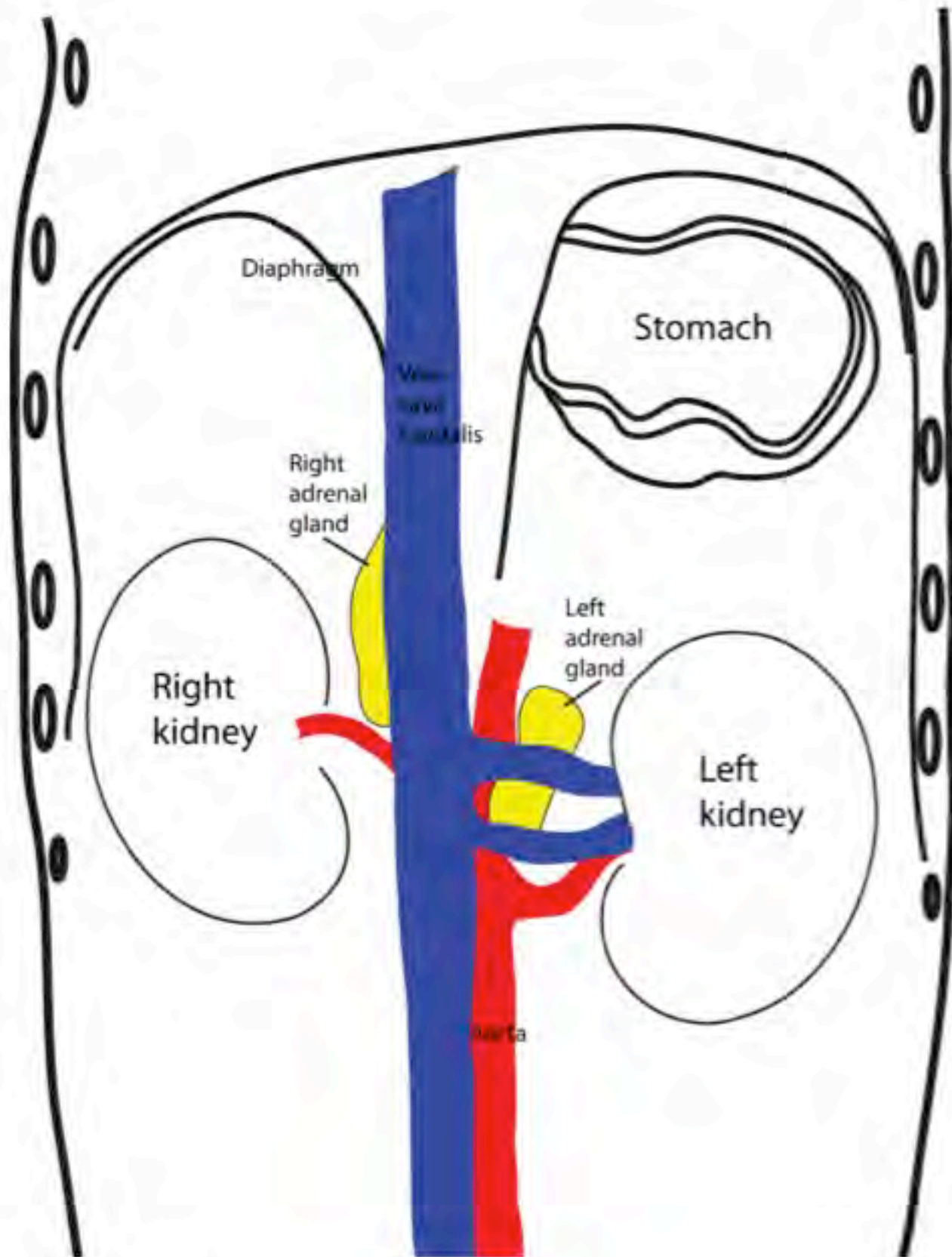
- dorsal: m. psoas minor, crus diaphragmatica
- (ventro)medial: v. cava caudalis
- ventrolateral: right kidney
- cranioventral: right lateral liver lobe

-The left adrenal gland is located at the level of the second lumbar vertebra, and more cranially with respect to its corresponding kidney than the right adrenal gland. The left adrenal gland is bordered by the following structures.

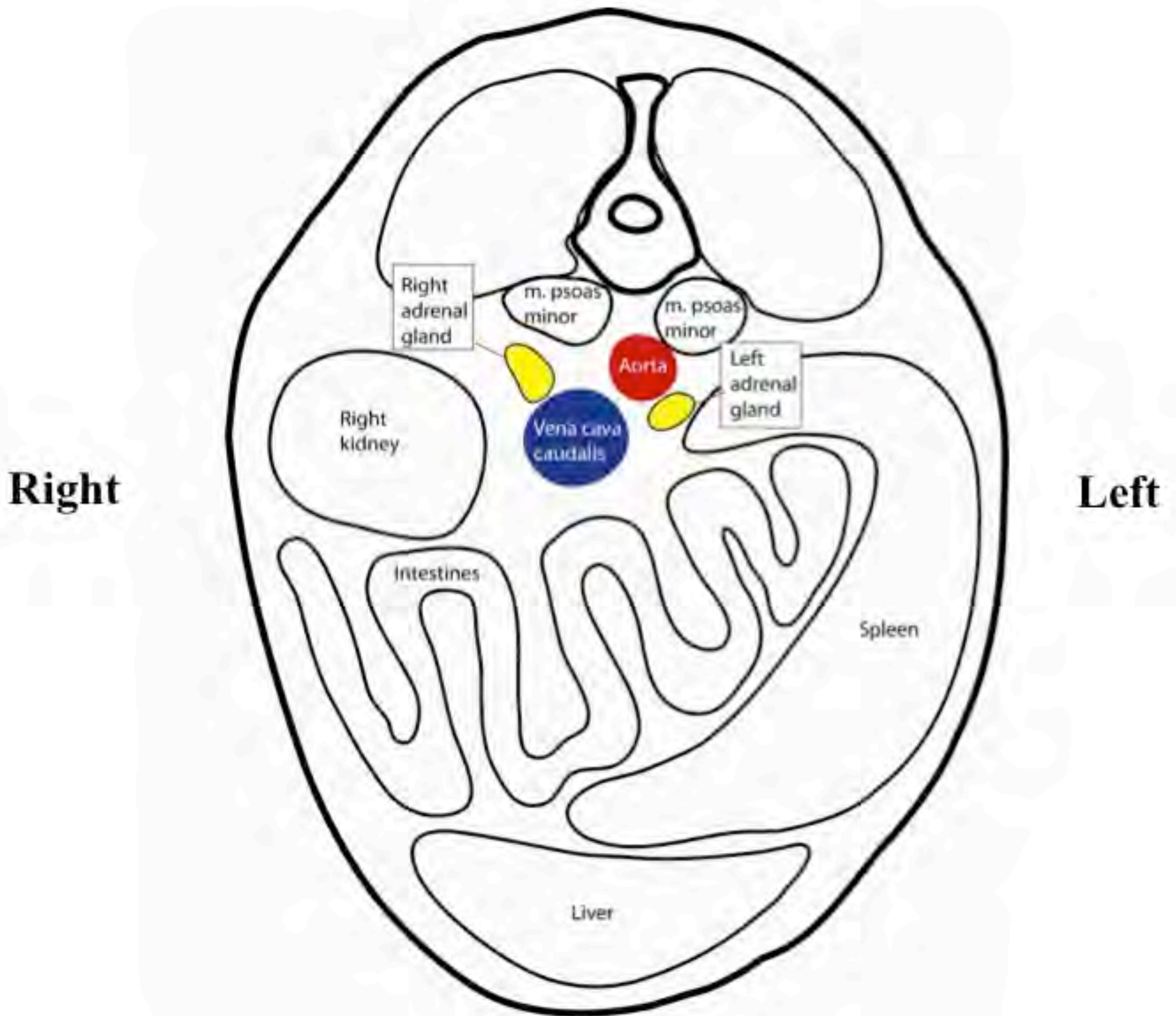
- dorsally: m psoas minor
- (dorso)medially: aorta
- ventrally: spleen
- laterally: left kidney

A venous vessel (v. abdominalis cranialis) passes ventrally over the central parts of the left adrenal gland.

Adrenal glands ventrolateral view



Adrenal glands transversal view



How do adrenal glands look?

The right adrenal gland is more elongated and thin (especially large dogs) and may have a comma-shaped or bent arrow conformation.

The left adrenal gland is shaped like a peanut shell (dumbbell).

The normal adrenal glands are generally small and depends on body size. As a guideline, the following sizes can be used: length 2-3 cm, width 1 cm, ventrodorsal thickness 0.5 cm.

- Small adrenal glands can be expected in dogs with primary hypoadrenocorticism due to immune mediated adrenalitis and in dogs with secondary hypoadrenocorticism (uncommon).
- Enlarged adrenal glands in dogs with hypoadrenocorticism can be associated with tumor infiltration, granulomatous inflammation/infection or congenital adrenal hypertrophy (diagnosed in humans)

A regional hilar lymphnode can easily be mistaken for an adrenal gland.